

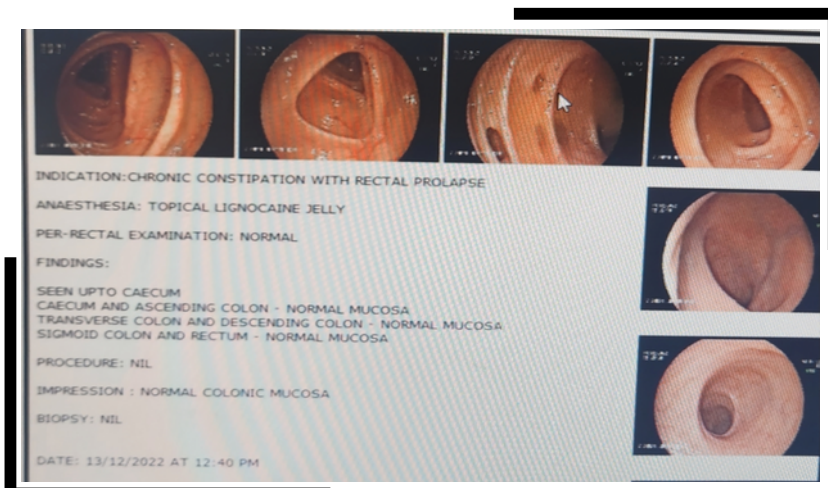
AN INTERESTING CASE OF RECTAL PROLAPSE

An 81 yr old man had a very unusual problem of something large coming out of his anal verge during defecation since 3-4 months. The prolapsed component was around 4-5 cms long and would not go in on its own. He had to manually reposit it.

He had a history of hypertension & breathlessness on climbing stairs, his investigation revealed ECHO 35% ejection fraction, Xray Chest showed cardiomegaly, and rest blood parameters was normal.

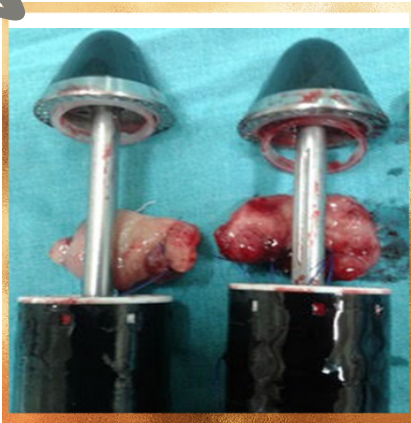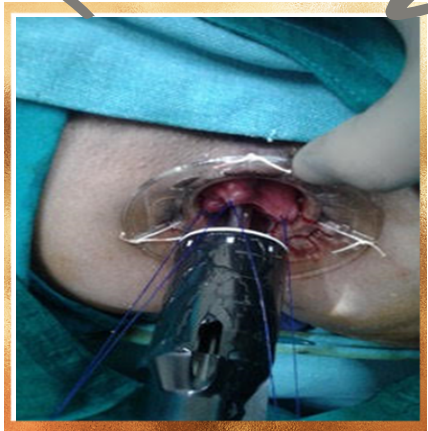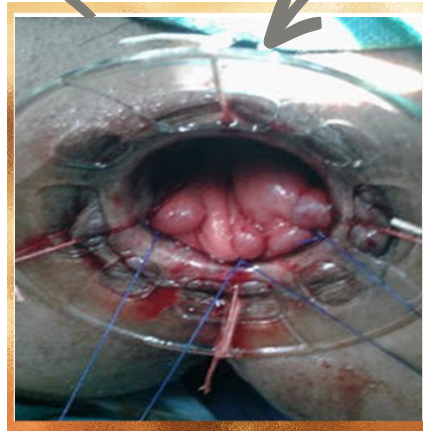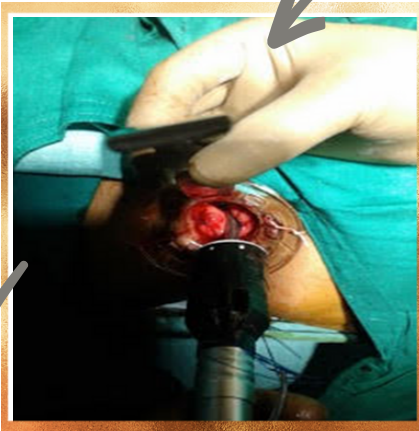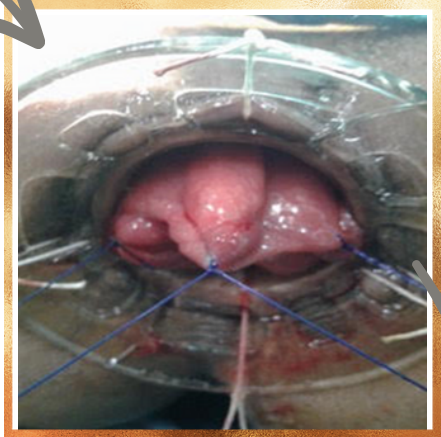
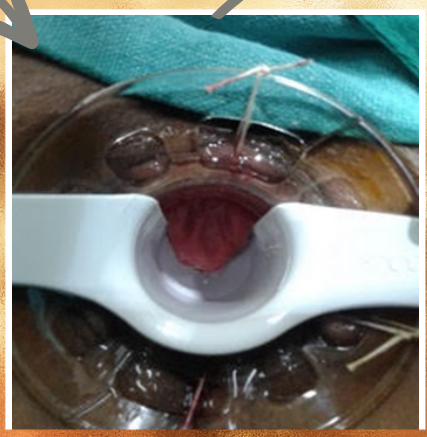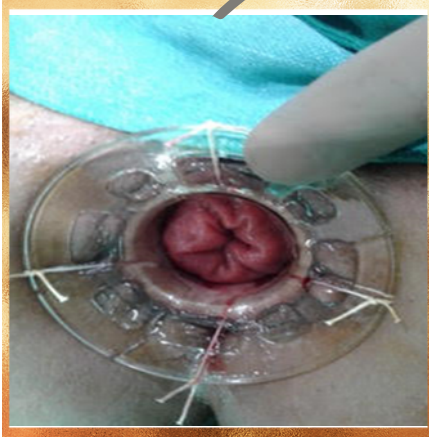On examination, a large rectal prolapse around 4-5cms was found, involving all the layers of rectum.

After proper workup he was advised Surgery for Rectal Prolapse STARR Procedure, that was performed by Dr. Akshay Sharma, Laparoscopy & Colo-Rectal Surgeon at Vishesh Jupiter Hospital, Indore.



STARR - STAPLED TRANS ANAL RECTAL RESECTION

- Minimal Invasive
- Less Co-morbid
- Less Duration
- Faster Recovery



SEPTA BLOCK


Simplified easily reproducible Pudendal Nerve Block

Premedication Pentazocine 30 mg and Phenargan

During Procedure 2.0 mg of Midazolam diluted in 10 ml saline given in titrated dose.

Patient is positioned in the Lithotomy position

In this technique the anaesthetic solution is injected into the centre of Ischioanal fossa from where it percolates down to the pudendal neurovascular bundle, which is situated at the base of the fossa.



His pre-anasthetist check up showed very high risk for Anesthesia. So, we planned his surgery in septa block and patient well stood the procedure. The operative time was 40-45 minutes, and the patient was discharged the very next day.



Dr. Akshay Sharma

Laparoscopy & Colo-Rectal Surgeon
MBBS, MS, FMAS, FIAGES & Master course in
Minimal Invasive Proctology.

Post op;

- Patient was given liquid & soft diet after 2 hours.
- Self Ambulated
- Seitz bath next morning
- Passed motion without any prolapsed

Prolapse of mucous membrane or entire rectum

Common in children n elderly patient

Partial - Approx 3.5cm from anal verge only mucosa
n sub mucosa descends without muscular layer

Complete - Procidentia contains all layers usually
5cms - 15 cms.

RECTAL PROLAPSE

- No Anaesthesia
- No IV Fluids/ No Injectables
- Minimal Invasive
 - No Incision
 - Less Pain
 - Faster Recovery
- Early Start of Diet / Early Ambulation
- Early Discharge
- Early Resume to Normal Life

ADVANTAGES

