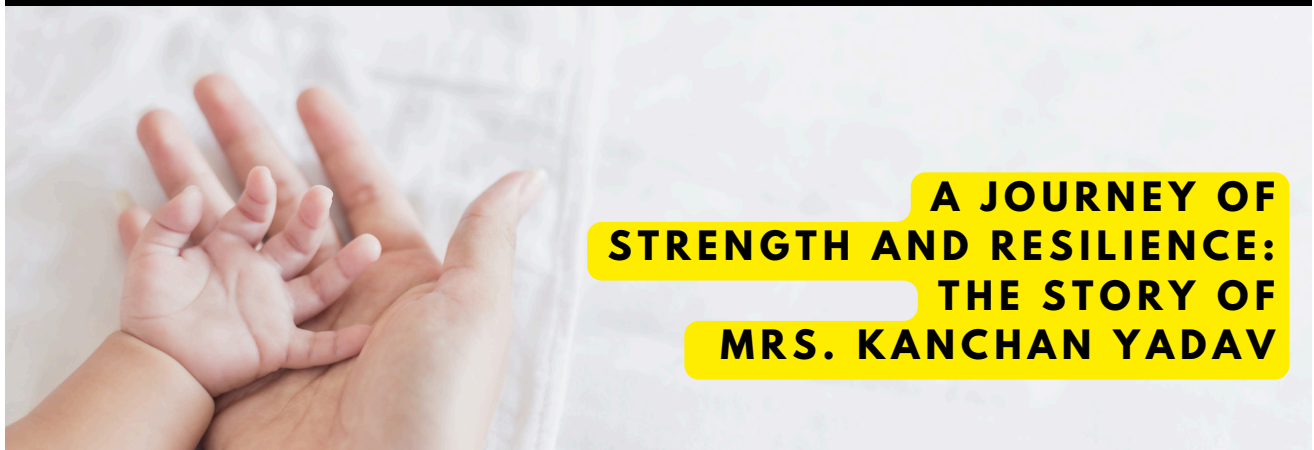

THANE · 2024 · VOL 12



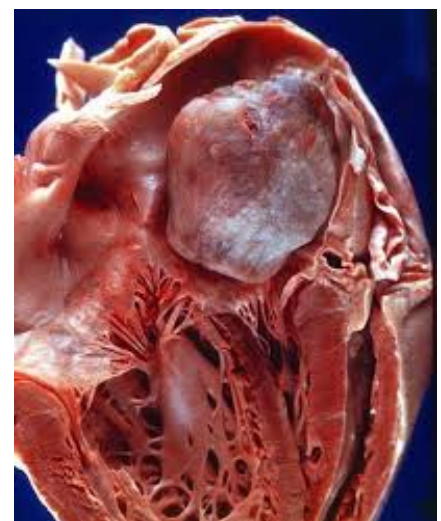
## March 2024: An Unexpected Challenge

Mrs. Kanchan Ravikumar Yadav, a 33-year-old woman in her **30th week of pregnancy**, was enjoying a seemingly smooth pregnancy journey. However, her life took an unexpected turn when she suddenly experienced right-sided weakness and an inability to speak. Concerned, her family rushed her to a nearby hospital where doctors found that she had significant right-side weakness and facial involvement. After receiving initial treatment, she was transferred to Jupiter Hospital for further management.

Upon her admission to the ICU under the care of Dr. Ashutosh Ajgaonkar, Consultant - Obstetrician and Gynaecologist a 2D Echo revealed **a large, mobile mass in her left atrium, suspected to be a myxoma**. This rare heart tumor posed a significant risk to both her and her unborn child.

The medical team quickly mobilized, with neurology consultations from Dr. Aniruddha More and cardiology input from Dr. Nitin Burkule. It was clear that early surgical intervention was necessary.

But subsequently, a grave dilemma arose. Was the baby to be delivered prematurely?..



## Surgical Intervention

On March 18th, under the skilled hands of Cardiac Surgeon Dr. Jayesh Dhareshwar, and with the support of anesthetist Dr. Amrapali Naik and Senior Perfusionist Mr. Ravindra, **Mrs. Kanchan underwent a successful excision of the left atrial myxoma.** The team patiently monitored the baby's vitals, ensuring that both blood pressure remained stable and that adequate blood supply was provided to both the mother and the child. The procedure went smoothly, and she was soon stable in the ICU. Remarkably, an ultrasound confirmed that her baby, at nearly 30 weeks, was also doing well, with a healthy fetal weight.

On March 26th, after ensuring both mother and baby were stable, she was discharged, her heart condition resolved, and her pregnancy progressing normally.

## May 2024: A Joyful Arrival

Two months later, Mrs. Kanchan returned to Jupiter Hospital, this time with a much happier purpose. At 37.6 weeks of gestation and with a history of a previous LSCS and placenta previa, she was admitted for her scheduled cesarean section.

On May 18th, under spinal anesthesia and Caesarean section by Dr. Ashutosh Ajgaonkar she delivered a beautiful, healthy baby girl weighing 3.11 kg. The baby cried immediately after birth, signaling her robust health. A thorough examination confirmed that the newborn was in perfect condition, with no visible abnormalities.

Both mother and baby were discharged on May 21st, healthy and full of hope. Baby of Kanchan, passed her hearing test with flying colors and was declared fit for discharge, just like her mother.



**THIS STORY OF MRS. KANCHAN RAVIKUMAR YADAV HIGHLIGHTS THE EXCEPTIONAL CARE PROVIDED BY THE MULTIDISCIPLINARY TEAM AT JUPITER HOSPITAL, WHOSE DEDICATION AND EXPERTISE ENSURED THE SAFETY AND WELL-BEING OF BOTH MOTHER AND CHILD THROUGH A CHALLENGING AND ULTIMATELY JOYOUS JOURNEY.**